

Does Left Ventricular Function On Echocardiography At Rest And Exercise Predict Recoarctation In Children With Postoperative Coarctation Of Aorta

Postoperatif Aort Koarktasyonlu Çocuklarda, İstirahat ve Egzersizdeki Ekokardiyografik Sol Ventrikül Fonksiyonları Rekoarktasyonu Tahmin Ettirir mi?

Naci Öner,

* Kemal Nişli,

** Taner Yavuz,

Ayşe Yıldırım,

* Ümrah Aydoğan,

* Aygün Dindar,

*** Emin Tireli,

***Türkan Tansel,

* Rukiye Eker Ömeroğlu.

Kartal Koşuyolu Yüksek İhtisas
Eğitim ve Araştırma Hastanesi,
Department of Pediatric

Cardiology,

* Istanbul University Faculty
of Medicine, Department of
Pediatric Cardiology,

** Zeynep Kamil Hospital,
Department of Pediatric

Cardiology,

*** Istanbul University Faculty of
Medicine,
Department of
Cardiovascular Surgery,

Received: 02.12.2010

Accepted: 04.02.2011

Correspondence

Naci Öner, MD

Kartal Koşuyolu Yüksek İhtisas
Eğitim ve Araştırma Hastanesi,

Department of Pediatric
Cardiology,

Istanbul, Turkey.

e-mail

nacioner@yahoo.com

ABSTRACT

Objective: The aim of this study was to evaluate ventricular performance before and after exercise in children who had surgically repaired coarctation of aorta (CoA) by using two dimensional, M- mode and Doppler echocardiography and to determine whether this method can be used for identifying recoarctation in comparison to Magnetic Resonance Imaging (MRI).

Design: We studied on 24 patients who were operated for CoA previously and compared with 24 healthy controls. Blood pressure monitoring, echocardiographies at rest and after exercise and MRI of aortic arc were performed. Patients having had $\geq 30\%$ of isthmic stenosis on MRI was diagnosed as recoarctation. The patient group were divided as Group A (patient without recoarctation) and Group B (patients with recoarctation) and were compared.

Results: We found that 8 of 24 patients had recoarctation on MRI. Physical examination and echocardiographic evaluation revealed that hypertension on the right arm at rest, systolic and diastolic hypotension on the left leg after exercise, increased values of ejection fraction, fractioned shortening and aortic gradient on exercise may predict more than 30% narrowing of the aortic isthmus.

Conclusion: These findings can be useful as predictors for recoarctation.

Key Words: Coarctation of aorta, exercise, Doppler echocardiography, Magnetic Resonance Imaging, MRI, recoarctation.

ÖZET

Amaç: Bu çalışmanın amacı cerrahi olarak düzeltilmiş aort koarktasyonlu çocuklarda egzersiz öncesi ve sonrası yapılan 2 boyutlu, M-mod ve Doppler ekokardiyografiyle değerlendirilen sol ventrikül fonksiyonlarının, rekoarktasyonu gösterip göstermediğinin Magnetik Rezonans Görüntüleme ile kıyaslanarak belirlenmesidir.

Gereç ve Yöntemler: Aort koarktasyonu operasyonu geçiren 24 çocuk, 24 sağlıklı kontrolle karşılaştırıldı. Kan basıncı monitorizasyonu, istirahat ve egzersizde ekokardiyografik değerlendirme ve MRG yapıldı. MRG'de %30 ve daha çok isthmus daralması görülen çocuklar rekoarktasyon olarak değerlendirildi. Rekoarktasyon grubu Grup A, kontrol grubu Grup B olarak belirlendi.

Bulgular: MRG'de 24 hasta çocuktan 8'inde rekoarktasyon saptandı. Fizik muayene ve ekokardiyografiye göre istirahatte sağ kolda hipertansiyonu olma, egzersizle bacadaki sisto-

lik ve diyastolik hipotansiyon olma, ekokardiyografide yüksek ejeksiyon fraksiyonu, fraksiyone kısalma ve aortik gradyent olması rekoarktasyon göstergesi olarak kabul edildi.

Sonuçlar: Bu bulgular rekoarktasyonu göstermesi açısından önemlidir.

Anahtar Kelimeler: Aort koarktasyonu; Egzersiz; ekokardiyografi, dopler; Manyetik rezonans görüntüleme.

INTRODUCTION

Coarctation of aorta (CoA) is simply defined as narrowing of the proximal descending aorta and commonly located just distal to the origin of the left subclavian artery. It is encountered approximately 0.1 % of newborns and occurs in 8% to 10% of all cases of congenital heart defects (1). The standard treatment of CoA is surgical. However, when the patients can not be tolerated surgery or when recoarctation occur after surgery, balloon angioplasty should be performed. In the last two decades, treatment by catheter intervention has become popular using either balloon angioplasty or primary stent implantation (2). Coarctectomy with end-to-side anastomosis, subclavian artery flap, overlay patch and a conduit insertion between the ascending and descending aorta are the proposed surgical methods for treatment of CoA (3). After surgery, myocardial dysfunction, dilatation or dissection of aorta and recoarctation are well known complications and these patients should be closely followed up for these complications (4-7). Using invasive and expensive techniques such as Magnetic Resonance Imaging (MRI) and angiography for routine evaluation of postcoarctectomy patients can not be justified, therefore non-invasive methods should be put into use for the evaluation of recoarctation. The aim of this study was to determine whether rest and exercise Doppler echocardiographic left ventricular performance and blood pressure values are predictive for recoarctation, in comparison with MRI.

MATERIAL AND METHODS

Patients

This study was carried out at Istanbul University, Faculty of Medicine, and Department of Pediatric Cardiology. Forty six patients aged between 4 to 20 years who had undergone coarctectomy at least six months ago, were invited for the study. Participation was voluntary and both parental and patients' approvals were obtained. This study was approved by the local Ethics Committee of the Istanbul University Faculty of Medicine.

Patients with additional cardiac abnormalities except bicuspid aortic valves were excluded from the study. Patients who had problems which negatively affect the exercise protocol such as acute and chronic disorders (renal, hepatic disease), neuromotor and mental retardation were also excluded. Thirty patients participated in the study and 5 of them could not complete the exercise protocol due to severe hypertension (two patients) and discordance and refusal during the application of the protocol. One patient who had had balloon angioplasty before the surgery was

also discarded from study. Finally, the patient group comprised 24 patients (13 boys and 11 girls, mean age of 10.3 ± 3.9 years, range 5.5 to 19 years) and compared with 24 healthy controls (12 boys and 12 girls, mean age of 10.1 ± 2.42 years, range 7 to 14 years). Children who were diagnosed as innocent murmur in Pediatric Cardiology Clinic were chosen as a control group.

The data concerning the following parameters were derived from the medical records of patients: operation time, preoperative pressure gradients and operation type. The age at operation ranged from newborn period to 15 years (mean 6.5 years) and preoperative pressure gradients, measured at cardiac catheterization, ranged from 24 to 90 mmHg (mean: 56.5). Coarctectomy with end-to-side anastomosis were performed in 19 patients and patch-plasty was required in 5 patients. Postoperative follow-up duration ranged from 6 months to 13 years (mean 3.6 years).

Methods

Blood pressure monitoring, two dimensional, M-Mode and Doppler echocardiographies at rest and after exercise were performed in all subjects. After 15 minutes of resting in the supine position, physical examination was performed and blood pressures of the upper and lower extremities were measured simultaneously with an automatic oscillometric method (Medilink DP 2000), using suitable cuffs for extremities.

Exercise test was performed with motorized treadmill (Marquette, Centra) by using Bruce protocol (8), which involves increasing the grade and the speed of the treadmill every 3 minutes, by using Marquette HT 7 controller. The cuffs of sphygmomanometer were already in place, so simultaneous blood pressure measurements of the upper and lower limbs and electrocardiogram (ECG) tracing were possible during the procedure.

Two dimensional and M-Mode echocardiography were performed in supine position at rest and immediately following exercise, using a 3.5 and 2-MHz transducer (Hewlett Packard Sonos 1000) positioned at the parasternal long axis and continuous-wave Doppler studies were performed at suprasternal notch. Doppler and blood pressure variables from the three consecutive recordings were obtained, and the mean value was used. The data concerning the following parameters were derived from the echocardiography: interventricular septum end-systolic thickness (IVSs), interventricular septum end-diastolic diameter (IVSd), left ventricular end-systolic diameter (LVISd), left ventricular end-diastolic diameter (LVIDd), systolic left ventricular posterior wall diameter (LVPWs),

diastolic left ventricular posterior wall diameter (LVPWd), systolic left ventricular mass (LV mass-s) gr/m², diastolic left ventricular mass (LV mass-d) gr/m², fractioned shortening (FS), ejection fraction (EF), end-systolic volume (ESV), end-diastolic volume (EDV), cardiac output (CO), stroke volume (SV). The peak systolic gradient (PG) over the isthmus was computed using the modified Bernoulli equation: $PG = 4 \times (v_2^2 - v_1^2)$ where v_1 is the peak flow velocity in the ascending aorta and v_2 is the peak flow velocity in the descending aorta (9).

In the patient group MRI was also performed with a 1.5 T MRI scanner (Magnetom, Vision, Siemens, Erlangen) in the supine position using the body coil and ECG triggering in the same time with echocardiographic examination. Axial, oblique sagittal and coronal T1 weighted spin echo images (TR 400, TE 12, matrix 512 x 160, 5 acquisitions, and slice thickness 6 mm) were obtained. The diameter of the isthmus and the descending aorta at the level of the diaphragm were measured, and the residual narrowing at the isthmus was expressed as $[1 - (\text{diameter isthmus} / \text{diameter descending aorta})] \times 100 = (\% \text{ stenosis})$ (10). Patients having had $\geq 30\%$ of isthmic stenosis was diagnosed as recoarctation. The patient group were divided as Group A (patient without recoarctation) and Group B (patients with recoarctation).

Statistical Analysis

All data are expressed as the mean \pm SD (min-max). Comparison between patients and controls and patients' subgroups (Group A and Group B) were made by means of Mann Whitney U test and 2 tests. Differences were considered significant at $p < 0.05$. All statistical analyses were performed by using the Minitab Release 13 statistical package (Ref. Number: wcp 133100197).

RESULTS

The results of blood pressure evaluations and echocardiography of the patients and controls during rest and exercise are shown in Table 1 and 2. There was no statistical difference between patients and controls with respect to right arm systolic and diastolic blood pressure values during resting and after exercise. Resting left leg systolic blood pressure values were not statistically different between patients and controls, whereas after exercise, patients' left leg systolic and diastolic blood pressure values were found to be lower than those in controls ($p < 0.05$) (Table 1).

We found higher IVSs, IVSd, LV mass-s, LV mass-d at rest and IVSd, LVPWd, LV mass-s and LV mass-d after exercise in patients than those in controls ($p < 0.05$). Other parameters which were measured by echocardiography were not different between patients and controls (Table 2).

Table 1. Blood pressure data of subjects at rest and after exercise.

Blood Pressures	RESTING			AFTER EXERCISE		
	Controls	Patients	p	Controls	Patients	p
Right Arm Systole	119.0 \pm 9.4 (100-135)	123.2 \pm 22.4 (90-170)	NS	161.5 \pm 8.8 (150-180)	166 \pm 10.8 (150-185)	NS
Right Arm Diastole	76.0 \pm 7.4 (60-85)	64.4 \pm 15.7 (40-95)	NS	88.0 \pm 6.3 (80-100)	88.0 \pm 9.2 (69-100)	NS
Left Leg Systole	121.5 \pm 10.5 (100-130)	114.7 \pm 25.4 (80-168)	NS	158.0 \pm 5.9 (150-170)	135.7 \pm 30.3 (85-180)	NS
Left Le Diastole	74.0 \pm 6.6 (60-80)	64.8 \pm 15.9 (40-98)	NS	86.5 \pm 6.3 (80-95)	76.0 \pm 15.8 (42-100)	NS

Values as expressed as mean \pm SD (min-max)/mean \pm SD (min-max)

Table 2. Echocardiographic data of subjects at rest and after exercise.

	RESTING			AFTER EXERCISE		
	Controls	Patients	p	Controls	Patients	p
IVSs	1.01 \pm 0.10	1.29 \pm 0.24	$p < 0.05$	1.11 \pm 0.2	1.26 \pm 0.32	NS
IVSd	0.63 \pm 0.20	0.88 \pm 0.26	$p < 0.05$	0.60 \pm 0.2	0.86 \pm 1.9	$p < 0.05$
LVIDs	2.53 \pm 0.50	2.59 \pm 0.66	NS	2.16 \pm 0.48	2.23 \pm 0.6	NS
LVIDd	4.17 \pm 0.60	3.99 \pm 0.70	NS	4.0 \pm 0.5	4.15 \pm 0.57	NS
LVPWs	1.07 \pm 0.2	1.18 \pm 0.29	NS	1.21 \pm 0.3	1.09 \pm 0.46	NS
LVPWd	0.66 \pm 0.2	0.77 \pm 0.21	NS	0.62 \pm 0.1	0.85 \pm 0.25	$p < 0.05$
LV mass-s	56.4 \pm 9.6	81.0 \pm 29.8	$p < 0.05$	61.94 \pm 22.8	101.6 \pm 31.4	$p < 0.05$
LV mass-d	55.9 \pm 13.9	84.0 \pm 47.7	$p < 0.05$	56.94 \pm 21.9	102.5 \pm 30.0	$p < 0.05$
FS	38.62 \pm 4.3	41.3 \pm 4.0	NS	48.6 \pm 7.8	45.4 \pm 7.6	NS
EF	69.2 \pm 1.9	70.8 \pm 5.4	NS	0.80 \pm 0.1	0.78 \pm 0.1	NS
ESV	21.0 \pm 6.6	24.3 \pm 10.1	NS	14.25 \pm 6.6	17.0 \pm 9.6	NS
EDV	68.73 \pm 20.6	80.9 \pm 29.1	NS	68.4 \pm 18.7	79.0 \pm 8.2	NS
CO	4.37 \pm 1.4	4.69 \pm 1.9	NS	9.74 \pm 4.1	8.92 \pm 5.2	NS
SV	47.61 \pm 15.7	55.2 \pm 20.9	NS	62.42 \pm 6.9	58.5 \pm 22.6	NS

Values as expressed as mean \pm SD, IVSs: systolic interventricular septum thickness, IVSd: diastolic interventricular septum thickness, LVIDs: systolic left ventricular diameter, LVIDd: diastolic left ventricular diameter, LVPWs: systolic left ventricle posterior wall thickness, LVPWd: diastolic left ventricle posterior wall thickness, LV: left ventricle, FS: fractioned shortening, EF: Ejection fraction (%), ESV: end-systolic volume, EDV: end-diastolic volume, CO: cardiac output, SV: stroke volume

According to MRI results; Group A (patients who had $< 30\%$ isthmic stenosis) comprised of 16 patients (8 girls, 8

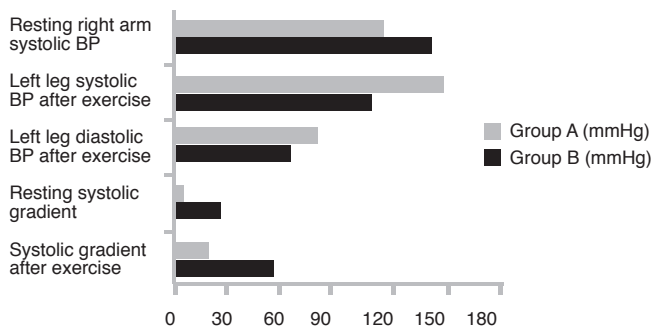
boys, mean age 10.1 ± 4.2 years) and Group B (patients who had $\geq 30\%$ isthmic stenosis) comprised of 8 patients (3 girl, 5 boys, mean age 10.8 ± 3.4 years). The results of the blood pressure of the four extremities of Group A and B during resting and exercise are shown in Table 3 and Figure 1.

Table 3. Blood pressure data of Group A and Group B patients at rest and after exercise.

Blood pressure	RESTING			AFTER EXERCISE		
	Group A	Group B	p	Group A	Group B	p
Right arm systole	115.4±21.3 (90-172)	138.8±15.9 (120-165)	p<0.05	165.7±10.0 (152-180)	167.0±13.7 (150-185)	NS
Right arm diastole	60.9±11.3 (40-80)	71.5±21.1 (40-95)	NS	88.2±10.0 (69-100)	88.5±8.0 (80-100)	NS
Left leg systole	116.3±23.6 (80-168)	111.5±29.9 (80-150)	NS	148.2±25.5 (90-180)	110.7±23.5 (85-145)	p<0.05
Left leg diastole	63.9±14.3 (40-98)	64.1±19.7 (40-90)	NS	81.4±13.8 (50-100)	65.3±14.4 (33-92)	p<0.05
Systolic gradient	6.7±20.5 (-22-25)	26.7±31.2 (-20-70)	p<0.05	18.2±23.3 (0-70)	56.3±22.3 (33-92)	p<0.05

Values as expressed as mean \pm SD (min-max)

Figure 1: Right arm systolic pressure, systolic gradient at rest and left leg systolic and diastolic pressure, systolic gradient after exercise are shown in Group A and B.



We found higher values of right arm systolic blood pressure at rest and systolic blood pressure gradient after exercise, lower left leg systolic and diastolic blood pressure after exercise in Group B than those in Group A. Although any statistical differences were found to be on resting echocardiographic findings between Group A and B, we found higher values of FS, EF and peak systolic gradient over the aortic isthmus on echocardiography in patients belong to Group B than those in Group A (Table 4, Fig 2).

Table 4. Echocardiographic data of Group A and Group B patients at rest and after exercise.

	RESTING			AFTER EXERCISE		
	Group A	Group B	p	Group A	Group B	p
Gradient	23.6±13.9	35.6±18.6	NS	32.1±15.0	73.8±22.0	p<0.05
IVSs	1.17 ±0.24	1.23±0.25	NS	1.18±0.27	1.42±0.38	NS
IVSd	0.87±0.27	0.91±0.25	NS	0.83±0.21	0.90±0.13	NS
LVIDd	4.19±0.56	3.61±0.83	NS	4.21±0.58	4.04±0.6	NS
LVIDs	2.65±0.45	2.48±0.98	NS	2.34±0.58	2.02±0.5	NS
LVPWd	0.75±0.22	0.82±0.21	NS	0.83±0.26	0.87±0.26	NS
LVPWs	1.12±0.29	1.31±0.27	NS	1.07±0.46	1.14±0.48	NS
FS	40.5±4.2	42.9±3.2	NS	42.6±6.2	50.9±7.6	p<0.05
LV mass s	74.3±26.9	91.1±33.7	NS	98.6±29.5	105.6 ±36.4	NS
LV mass d	79.7±17.2	83.6±26.0	NS	94.8±24.6	112.7±35.6	NS
EDV	86.6±30.7	73.4±27.6	NS	72.6±27.1	74.1±31.3	NS
ESV	28.4±9.5	18.9±8.8	NS	20.17±7.9	12.69±10.6	NS
EF	69.6±5.5	74.4±4.4	NS	75.0±6.8	0.86±3.5	p<0.05
CO	5.08±2.1	4.17±1.51	NS	9.48±4.5	9.27±3.92	NS
SV	57.4±21.8	52.3 ±21.2	NS	58.3±23.9	58.7±23.0	NS

Values as expressed as mean \pm SD, IVSs: systolic interventricular septum thickness, IVSd: diastolic interventricular septum thickness, LVIDs: systolic left ventricular diameter, LVIDd: diastolic left ventricular diameter, LVPWs: systolic left ventricle posterior wall thickness, LVPWd: diastolic left ventricle posterior wall thickness, LV: left ventricle, FS: fractioned shortening, EF: Ejection fraction (%), ESV: end-systolic volume, EDV: end-diastolic volume, CO: cardiac output, SV: stroke volume.

Figure 2: Aortic gradient, FS and EF are shown in Group A and B. These parameters were found to be higher in patients with recoarctation (Group B) ($p<0.05$).

Aortic gradient measured by Doppler echocardiography after exercise (mmHg)



Exercise time were not statistically different between patients (13.7 ± 3.8 min.) and controls (14.2 ± 1.2 min.) and Group A (14.1 ± 4.0 min.) and Group B (13.1 ± 3.8 min.).

DISCUSSION

Surgical repair of CoA, especially when performed in infancy, carries a subsequent risk of recoarctation (5). Invasive and expensive procedures such as angiography, transoesophageal echocardiography and MRI are used to evaluate anatomy of the aortic arch (11,12). It would appear to be useful to find some non-invasive methods, because these evaluations should be performed as frequent as once a year. Echocardiography, providing a reproducible measure of ventricular cavity and function, appears to be well suited for serial study of cardiac changes in operated CoA (5,9,10,13). Exercise testing is also an integral part of the physiological evaluation of postcoarctectomy and should be performed in all children if clinical condition permits (6).

Despite successful surgical repair of CoA, persistent alterations in systolic and diastolic left ventricular function have been shown in long term follow-up (4,14,15). This study demonstrated the existence of abnormalities in ventricular performance including increased LV mass-s, LV mass-d, IVSd at rest and after exercise and LVPWd after exercise in children with coarctectomy. Most reports suggest that hypertrophy decreases but does not disappear after successful elimination of after load stress such as CoA (14,15). Our study also supports this opinion. Hypertrophy remains due to unresolved concentric muscle mass elevation. Another mechanism that could produce the increased EF and sustained myocardial hypertrophy may be autonomic imbalance with chronically elevated catecholamine products (16). According to our study, when stenosis exceeding 30 %, gradual increase of left ventricular mass associated with increased EF and FS values and these findings suggest that recoarctation patients have exaggeratedly enhanced systolic performance.

Postoperative CoA patients were variably investigated with respect to residual hypertension, persistent ventricular adaptations, and increased stiffness of aorta; however predictors of recoarctation are insufficiently documented (2,14,15,17). In this study, we found that right arm systolic hypertension at rest, decreased blood pressure at lower limb and increased aortic gradient, EF and FS on Doppler echocardiography, just after exercise may suggest recoarctation. Similar findings on echocardiography have been confirmed by Donner et al. (17) in congenital aortic stenosis at rest identified indexes of increased ventricular pump function, including EF and FS, in conjunction with a decrease in ESV. Pelech et al. (4) also reported higher EF, FS and systolic IVS values in children with CoA after exercise. Similar studies for the prediction of recoarctation were performed on adult subjects. Guenthard et al. (18) reported that a systolic half time of >110 ms together with a diastolic

gradient of ≥ 17 mmHg on Doppler echocardiography after exercise is associated with recoarctation. Crepaz et al. (5) proposed that increased transisthmic systolic and diastolic pressure gradients and the systolic velocity half-time, measured at peak exercise by Doppler echocardiography can predict a recoarctation in operated CoA. Similarly, we found higher gradient after exercise measured by Doppler echocardiography in recoarctation patients. Moreover, we determined ≥ 30 % stenosis in all patients whose systolic gradient after exercise was more than 49 mmHg on Doppler echocardiography. We propose that, in patients who have undergone coarctation repair, these features may be useful as predictive features for recoarctation.

Several studies have found persistent hypertension at rest and/or as a response to exercise in coarctectomy patients. Exercise-induced hypertension after surgical repair of the CoA without apparent restenosis were also reported (6,11). Freed suggested that (19) when postexercise systolic pressure in the arm exceeds 200 mmHg, catheterization should be considered. We propose that if resting systolic right arm hypertension is associated with excessive increased left ventricular function and systolic gradient with exercise, recoarctation should be taken into consideration. Eleven out of 24 patients have right arm hypertension and 7 of 11 patients have >30 % stenosis while all have >19 % stenosis. Contrary to these results, some authors suggest that despite successful surgery of CoA, 30-65 % of children have hypertension after exercise and 11-15 % of them at rest. Gunthard et al. reported (20) that arm hypertension developing late after coarctation repair seems not to be related to residual stenosis. Postoperative follow-up period of our patients were short (4.7 ± 3.6 (1 to 13) years) and the varying results of these studies may be due to different follow-up time of these subjects.

The major limitation of this study is probably the inadequate number of patients. Only 24 patients were appropriate for the study, although our pediatric cardiology center is one of the reference centers in Turkey. Despite limitations, the data reported in this study still provides valuable information about children with recoarctation.

Our results also show that resting and exercise blood pressure measurements are not sufficient for prediction of recoarctation. Doppler echocardiography at rest and exercise should be performed for these cases. Yearly follow-up can be recommended in patients without significant gradient at rest and exercise while close follow-up and cardiac catheterization and intervention may be required in patients with systolic gradient >30 mmHg at exercise.

ACKNOWLEDGMENTS

We thank Prof. Betül Acunaş, M.D. for her critical review of the manuscript.

REFERENCES

1. Bernstein D. Epidemiology and genetic basis of congenital heart disease. In Behrman RE, Kliegman RE, Jenson HB (eds). *Nelson Textbook of Pediatrics*, 17th edn. Saunders, Philadelphia 2004;1499-502.
2. Hornung TS, Benson LN, McLaughlin PR. Interventions for aortic coarctation. *Cardiol. Rev.* 2002;10:139-48.
3. Younoszai AK, Reddy VM, Hanley FL, Brook MM. Intermediate term follow-up of the end-to-side aortic anastomosis for coarctation of aorta. *Ann. Thorac. Surg.* 2002;74:1631-4.
4. Pelech AN, Kartodihardjo W, Phys M, Balfe JA. Exercise in children before and after coarctectomy: Hemodynamic, echocardiographic, and biochemical assessment. *Am. Heart J.* 1986;112:1263-70.
5. Crepaz R, Pitscheider W, Oberhollenzer R, Zammarchi A, Knoll P, Erlicher A, Vedovello R, Mautone A, Morini G, Braitto E. Long-term follow-up in patients operated on for aortic coarctation. The echo-Doppler and MRI assessment of left ventricular function and the transisthmic gradient. *G. Ital. Cardiol.* 1993;23:767-76.
6. Goldberg B, Fripp RR, Lister G. Effects of physical training on exercise performance of children following surgical repair of the congenital heart disease. *Pediatrics* 1981;68:691-9.
7. Toro-Salazar OH, Steinberger J, Thomas W, Rocchini AP, Carpenter B, Moller JH. Long term follow-up of patients after coarctation of the aorta repair. *Am. J. Cardiol.* 2002;89:541-7.
8. Froelicher VF, Myers J, Follansbee WP, Labovitz AJ. *Exercise and the Heart*, 3rd ed, St. Louis, Missouri, Mosby-Year Book, 1993.
9. Hatle L, Angelsen B. Blood dynamics. In: *Doppler ultrasound in Cardiology*. Lea & Febiger, Philadelphia, 1982:22-31.
10. Stern HC, Locher D, Wallnöfer K. Non-invasive assessment of coarctation of aorta: comparative measurements by two dimensional echocardiography, magnetic resonance and angiography. *Pediatr. Cardiol.* 1991;12:1-5.
11. Araoz PA, Reddy GP, Tarnoff H, Roge CL, Higgins CB. MR findings of collateral circulation are more accurate measures of hemodynamic significance than arm-leg blood pressure gradient after repair of coarctation of the aorta. *J. Magn. Reson. Imaging* 2003;17:177-83.
12. Riquelme C, Laissy JP, Menegazzo D, Debray MP, Cinqualbre A, Langlois J, Schouman-Claeys E. MR imaging of coarctation of the aorta and its postoperative complications in adults : assessment with spin-echo and cine-MRI imaging. *Magn. Reson. Imaging* 1999;17:37-46.
13. De Mey S, Segers P, Coomans I, Verhaaren H, Verdonck P. Limitations of Doppler echocardiography for the post-operative evaluation of aortic coarctation. *J. Biomec.* 2001;34:951-60.
14. Carpenter MA, Dammann JF, Watson DD, Jedeikin R. Left ventricular hyperkinesia at rest and during exercise in normotensive patients 2 to 27 years after coarctation repair. *J. Am. Coll. Cardiol.* 1985;6:879-86.
15. Ong CM, Center CE, Gutierrez FR, Sekarski DR. Increase stiffness and persistent narrowing of the aorta after successful repair of coarctation of aorta: Relationship to left ventricular mass and blood pressure at rest and with exercise. *Am. Heart J.* 1992;123:1594-600.
16. Benedict CR, Phil D, Grahame-Smith G, Fisher A. Change in plasma catecholamines and dopamine beta-hydroxylase after corrective surgery for coarctation of aorta. *Circulation* 1978;57:598-602.
17. Donner R, Carabello BA, Black I, Spann JF. Left ventricular wall stress in compensated aortic stenosis in children. *Am. J. Cardiol.* 1983;51:946-51.
18. Guenthard J, Wyler F. Doppler echocardiography during exercise to predict residual narrowing of the aorta after coarctation resection. *Pediatr. Cardiol.* 1996;17:370-4.
19. Freed MD, Rocchini A, Rosenthal A, Nadas AS, Castaneda AR. Exercise-induced hypertension after surgical repair of the aorta. *Am. J. Cardiol.* 1979;43:253-8.
20. Gunthard J, Buser PT, Miettunen R, Hagmann A, Wyler F. Effects of morphologic restenosis, defined by MRI after coarctation repair, on blood pressure and arm-leg and Doppler gradients. *Angiology* 1996;47:1073-80.